

IMPLANT ASSISTED TIP EDGE: A CASE REPORT

Mukesh kumar¹, Manish goyal², Sonika sharma³, Sumit kumar⁴, Sonam Rastogi⁵

Professor¹, Principal and head², Private practitioner³, Senior lecturer^{4,5}

Department of orthodontics and dentofacial orthopedics, Teerthanker Mahaveer Dental college and Research Centre, Delhi Road Moradabad, Uttar Pradesh, India

Abstract

Background: Tip-Edge concept was first introduced at the kesling -Rocke orthodontics centre, Waistville Indiana, USA in 1986 by Dr P.C Kesling. This article reports the successful use of the Tip-Edge mechanics with mid line mini implant in an adult skeletal class II patient. This mechanics accomplishes a successful treatment result with minimal patient compliance.

Results: Conventional wrap around retainer was given in addition to bonded lingual retainer in the upper and the lower arch. The active treatment lasted for 22 months. The dental changes included achieving an ideal overjet and overbite, well aligned upper and lower arches, closing all spaces as well as accomplishing an esthetically pleasing soft tissue profile Post Acceptable root parallelism was attained and no root resorption occurred.

Conclusions: Tip-Edge concept produced the first edgewise appliance to allow the use of differential tooth movement. Tip-Edge combines an initial degree of tooth tipping, which greatly facilitates tooth movement. According to the result of this case we found that Implant assisted Tip-edge could be used in horizontal grower without changing the inter jaw relationship. The incisor proclination had drastically changed in upper and lower arches with a change in inter-incisal angle. The patient attained a pleasing soft tissue profile with the simplified mechanics, very light intraoral forces in combination with midline mini implant.

Key words: Clinical and radiographic examination.

Introduction

Tip-Edge concept was first introduced at the kesling -Rocke orthodontics centre, Waistville Indiana, USA in 1986 by Dr P.C Kesling⁽¹⁻³⁾. As its name suggests, Tip-Edge combines an initial degree of tooth tipping, which greatly facilitates tooth movement, prior to edgewise precision finishing therefore it is also known as "Differential straight wire technique". Based on extensive clinical experience, it is the belief of Dr. Kesling that Tip-Edge is the most significant innovation in fixed appliance orthodontics since the original edgewise bracket.⁽⁴⁻⁷⁾ Kesling determined that it was necessary for each tooth to tip either mesially or distally, but not in both directions. He found this to be true in the correction of all malocclusions whether they were treated with or without extraction, Furthermore he observed that the teeth mesial to the extraction site tipped distally while those distal to it tipped mesially.⁸ Kesling designed the Tip-Edge® bracket to provide all the benefits of differential tooth movement together with the control required to deliver a predetermined amount of tip and torque as found in pre-adjusted Edgewise systems. As we all know experimenting something is always a field of learning, so we decided for implant assisted tippedge.

Patient Report

Clinical and radiographic examination

A healthy, 18-year old male reported to the orthodontic department with the complaint of forwardly placed upper and lower front teeth. On extra oral examination, the patient showed a mesoprosopic facial pattern (Figure 1) with convex profile and an acute naso-labial angle. The

Patient presented with lip incompetency at rest along with full upper incisor display on smiling.

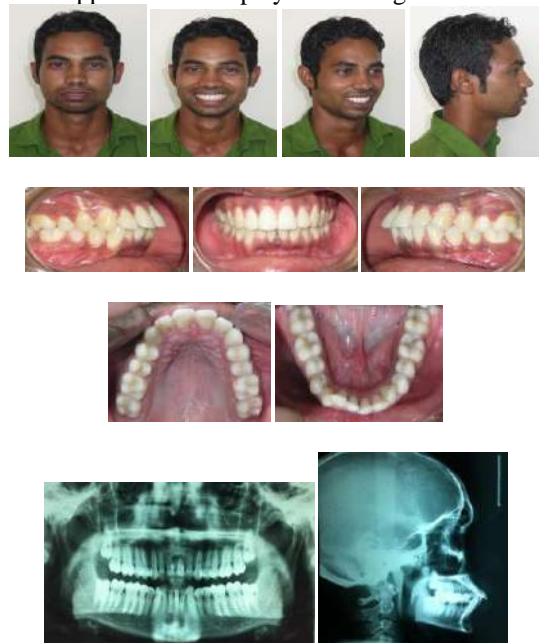

Fig1- Pretreatment Records.

The intraoral examination revealed proclined upper and lower anteriors along with mild crowding in the lower arch. Patient also presented with bilateral class I molar and canine relationship, 5mm of over jet, 2mm of overbite with curve of spee of 3mm (Figure 1). Both the upper and lower arches were U- shape and rotation was seen owing to crowding in the lower arch. The skeletal and dental midlines were found to be coinciding. The

panoramic radiograph revealed all permanent teeth along with optimum bone level for orthodontic treatment. The cephalogram displayed a skeletal class II relationship with a horizontal growth pattern.(Table 1)

Treatment Objectives

I. Stage I Objectives

- Alignment of upper and lower anterior segment.
- Correction of increased over jet.
- Maintain bite

II. Stage II Objectives

- Space closure mainly by retraction of labial segments.
- Maintain Stage I correction

III. Stage III Objectives

- Correction of torque and tip angles for each tooth individually.
- Final detailing
- To achieve lip competency and an aesthetically pleasing profile.

Treatment progress

Stage I Treatment:

The treatment was initiated with the extraction of first premolars in all quadrants. Banding of first molars was done along with bonding of all teeth except for the second premolars in both the arches. 0.014" inch Australian (AJ Wilcock) wire was placed in the upper arch while 0.014" niti (3M Unitek Nitinol Super Elastic Wire) wire placed in lower arch for the commencement of leveling and alignment.

This was followed by 0.016" inch Australian wire arch wires placement in both the arches, possessing a cuspid circle and a 25° anchorage bend. Light Class I elastics were given for retraction of maxillary and mandibular anterior teeth. By the end of Stage I, a reduced overjet was attained.

Stage II Treatment

0.018" high tensile strength Australian arch wire with cuspid circle was placed in both the arches. During stage I treatment, a 2mm lower midline shift developed towards the left side subsequent to lower anterior decrowding. For the midline correction, we continued class II traction on the left side and class III traction on the right side (Fig 2). After attaining matching midlines, we continued with the class II traction bilaterally to maintain the class I molar relationship through the upper anterior retraction and lower molar protraction as well as closing all the spaces. All the second premolars were bonded for level and alignment. Horizontally routed E-links were positioned from the premolar brackets for the residual Space closure. At the end of the stage II all the spaces were closed. So we decided to initiate stage III.

Stage III Treatment:

We continued the treatment by replacing 0.018" high tensile strength Australian arch wire to 0.017"X0.025"SS wire. We placed a mid line implant for the correction of the deep bite along with application of class I force bilaterally which was generated during the retraction phase. At the settling phase of the treatment we continued with 0.018" Australian arch wire in both the

arches by replacing the 0.017"X 0.025" SS wire along with uprighting spring to upright the rotated teeth (Figure 2). Complete occlusion settling could not be done as the patient wanted to have his brackets removed since he was relocating regarding his job. Hence an early debonding was done. Additionally, this patient had come to us with an excessive proclination which was corrected by extraction of first premolars followed by maximum retraction. On complete retraction we weren't left with more space to achieve the ideal proclination of upper incisor but we still managed to improve and achieve a good soft tissue profile. The patient was also very much satisfied with his treatment.

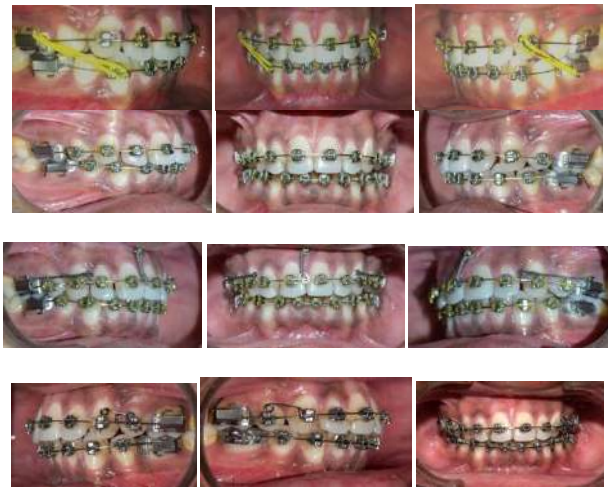

Figure 2- Mid treatment records.

Mid treatment patient's intra oral photograph showing class III elastics on right side and class II on left side, 0.017"x0.025" SS rectangular wire in upper and lower arch, Mid line implant along with class I force on both the sides (Biomechanics of intrusion uprighting springs in the upper arch premolar region placed bilaterally).

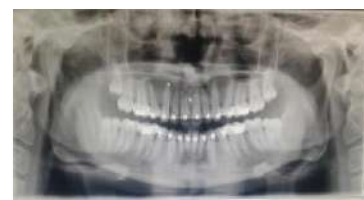

Fig 3-Mid treatment OPG of the patient.

Retention:

Conventional wrap around retainer was given in addition to bonded lingual retainer in the upper and the lower arch. The active treatment lasted for 22 months. The dental changes included achieving an ideal overjet and overbite, well aligned upper and lower arches, (Fig 4) closing all spaces as well as accomplishing an esthetically pleasing soft tissue profile Post Acceptable

root parallelism was attained and no root resorption occurred.

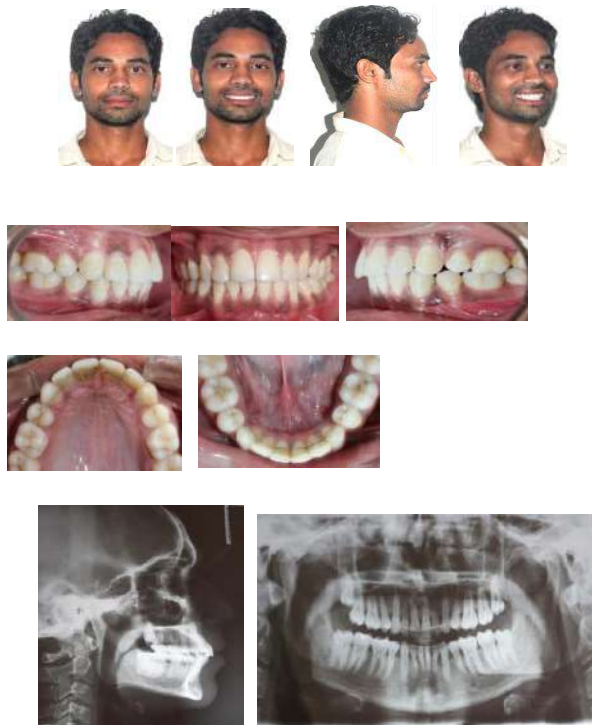

Fig 4- Post treatment records.

Cephalometrically (Table 1, Fig 4) a significant reduction in proclination was seen in upper incisor by 4mm and 12 degree and by 3 mm and 10 degree in the lower incisor respectively. Inter-incisal angle was also observed to be decreased by 29 degree. The soft tissue changes i.e. upper lip retruded by 4 mm and lower lip retruded by 4 mm. The profile of the patient changed from convex to straight type. There were no significant sagittal changes.

Cephalometric parameter	Pre treatment	Post treatment
SNA(degree)	79	78
SNB(degree)	76	76
ANB(degree)	03	02
U1 -NA(degree/mm)	34/10	26/6
U1- SN(degree)	118	100
L1- NB(degree/mm)	42/11	32/8
L1-MP(degree)	122	118
Interincisal Angle	91	120
Mandibular plane angle	27	28

Table 1 Pre and post cephalometric data.

A superimposition of the pre- and post treatment cephalometric tracing shows a decrease in proclination of upper and lower anterior teeth with a normal inter-incisal angle without any change in molar relationship.(Fig 5)

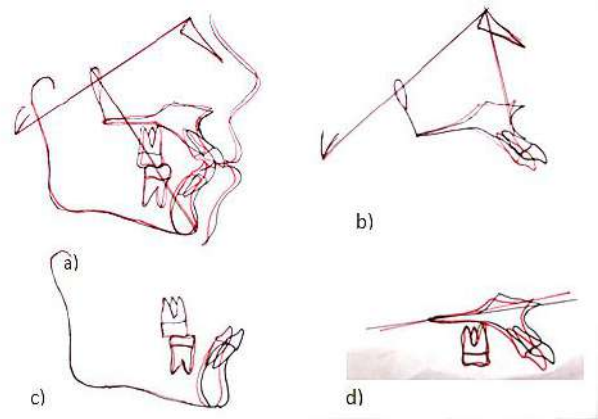


Fig 5.a) Basion Nasion at CC
 b) Basion Nasion at Nasion
 c) Mandible at internal structure
 d) ANS PNS at ANS

Discussion

Tip edge is the best mechanics for correction of bi dental protrusion. It is also well known for its excellent anchorage. Such cases like the one discussed, had severe proclination because of which tipping becomes the prime requirement during retraction and this appliance fulfills these requirements much efficiently.

Tip-edge mechanotherapy follows a distinctive way of starting a case by placing molar tubes on the first molars, anterior teeth bracket placement, and using a 0.016" Australian wire incorporated with bite opening bends to correct an overbite. However in this case we could not fit the patient with a stainless steel wire so we initiated with 0.014" niti wire in the lower arch.

Major tooth repositioning and apical base corrections can be accomplished with simplified mechanics and very light intraoral forces i.e elastomeric link to close the anterior spacing and the traction as necessary to achieve and maintain the incisors contacts.¹⁻⁵ The flexible main arch wire provides good control over rotation and, even in the lower arch in a high-angle case; the tipping of teeth into the extraction sites that one might expect is not seen. This is because of the added control given by the 0.018" Australian wire, giving all the advantages of tip-back mechanics.⁸

In this presented case we have seen patient generated deep bite during retraction. The tip edge mechanics involves placing an anchor bend in the arch wire which puts an extrusive force on molars and intrusive force on the incisors. The v-bend being closer to the molar, applies more force on the molar in comparison to the one on incisors. Hence tip edge mechanics applies minimal intrusive force. Moreover the use of Class II elastic for retraction nullifies the effects of anchor bend on upper incisors, so we decided upon placing a midline implant for the purpose of intrusion. The deep bite had generated as well as been corrected during the orthodontic

procedure by intrusion. During this period no radiographic records were taken which would have helped assess the amount of intrusion done.

Root resorption is one of the most serious problems of orthodontic treatment and intrusion is one type of tooth movement that has been suggested as a possible cause of root resorption. Deschild and Kaley and Phillip found no correlation with upper incisor intrusion and root resorption.⁹

Clinicians should use 0.014" high tensile stainless steel wire to fabricate an uprighting spring and the loop diameter should be at least 6 times the diameter of the wire (e.g. for wire diameter of 0.012", loop diameter should be 0.072") for its optimal performance. By Thurow, a lesser diameter will lead to produce the internal strain and increase the risk of failure.⁹ So, while using such kind of auxiliaries, care must be taken to prevent or minimize the side effects like labial crown movements, extrusion of anteriors, intrusion of posteriors and buccal crown movements. It is, therefore, absolutely essential that the base archwire be rigid enough, preferably 0.020" premium or 0.018" premium plus, pulse straightened Australian archwires to overcome the side effects.

By balancing the forces of intrusion and retraction, it is possible to guide the upper incisor apices palatally, thereby reducing the need for root torque. Therefore, the use of rectangular stainless steel wire early in treatment is not necessary, and these wires can be placed later for finishing. This again helps to reduce friction and to apply more predictable and reliably light forces to the teeth.¹⁰

Conclusion

Tip-Edge concept produced the first edgewise appliance to allow the use of differential tooth movement. Tip-Edge combines an initial degree of tooth tipping, which greatly facilitates tooth movement. According to the result of this case we found that Implant assisted Tip-edge could be used in horizontal growth without changing the inter-jaw relationship. The incisor proclination had drastically changed in upper and lower arches with a change in inter-incisal angle. The patient attained a pleasing soft tissue profile with the simplified mechanics, very light intraoral forces in combination with midline mini implant.

References

1. Kesling PC. Expanding the horizons of the edgewise arch wire slot. *American Journal of Orthodontics* 1988; 94: 26-37.
2. Kesling PC. Differential tooth movement Tip-Edge concept and the differential straight-arch technique. *Journal of Indian Orthodontics* 1988; 19: 31-35.
3. Kesling PC. Dynamics of the Tip-Edge bracket. *American Journal of Orthodontics* 1989; 96: 16-28.
4. Parkhouse RC. New thinking with Tip-Edge. *Kieferorthop* 1995; 9: 137-142.
5. Parkhouse RC. JIOS-Interviews: Dr Richard Parkhouse on Tip-Edge. *Journal of Indian Orthodontic Society* 1992; 23: 67-73.

6. Andrews LF. The straight wire appliance, origin, controversy, commentary. *J Clin Orthod.* 1976; IV: 49-114.

7. Begg PR, Kesling PC. *Begg Orthodontic Theory and Technique*. 3rd ed. Philadelphia, Pa: WB Saunders Company; 1982.

8. Helen Taylor. Use of a Tip-Edge Stage-1 Wire to Enhance Vertical Control during Straight Wire Treatment: Two Case Reports. *Angle Orthodontist*, 2003; Vol 73, 1:93-99.

9. Thurow CR. *Edgewise Orthodontics*. 4th ed. St. Louis: C.V. Mosby; 1982. p. 252

10. Deschild RW. A study of root resorption in treated class II Div I malocclusions, *Angle orthodontist*, 1969 vol 39 (pg. 231-245).

11. Jayne E. Harrison. Early experiences with Tip Edge appliances. *Br J Orthod*, 1998; 25:1-9.

Corresponding Author

Dr. Mukesh Kumar

Professor

Department of Orthodontics and Dentofacial Orthopaedics TMDCRC, Moradabad

Email: drmukeshortho@yahoo.co.in